WuXi AppTec

WuXi AppTec Ophthalmology Service

An Integrated Platform for Ocular Drug Development

Toxicology, Pharmacology and Drug Metabolism & Pharmacokinetics

Laboratory Testing Division

WuXi AppTec Ophthalmology Service

An international standard pre-clinical GLP and non-GLP ophthalmology lab.

WuXi AppTec Laboratory Testing Division, Toxicology department has established a professional ophthalmology laboratory so as to provide various services for ophthalmological studies. The ophthalmology lab is equipped with state-of-the-art set of examination equipment and led by an ophthalmologist and consisting of a professionally trained technical team. The provided services include comparative ophthalmologic examination in varieties of toxicity studies, eye irritation, new ocular drug toxicity and toxicokinetics, pharmacodynamics and pharmacokinetics. Our goal is to provide for new ocular drug development with the most advanced ocular PD, PK and Tox evaluation services.

Overview

- Standard with global regulatory compliance
- Passed NMPA, FDA and OECD inspections
- Full AAALAC accredited vivarium
- More than 30 well trained ocular staff
- Advanced ophthalmologic examination equipments
- Quick study starts, timely report deliveries

Our Service

- Comparative Ophthalmology in Toxicity Studies
- Eye Irritation Evaluation
- Ocular Toxicology/Toxicokinetics
- Ocular Pharmacokinetics/Pharmacology

An Integrated Platform for Ocular Drug Development

Eye examination and operation platforms

- Optical coherence tomography scan (OCT) + Fundus autofluorescence imaging (AF)
- Full-field/precise multi-focal Electrophysiology (fERG/fVEP/pERG/pVEP/mfERG)
- Fundus photograph (FP) + fundus fluorescein angiography (FFA)
- Direct/indirect ophthalmoscope examination
- Intraocular pressure monitoring (IOP)
- Slit lamp microscope examination
- Surgical microscope operation
- Laser photocoagulator modeling
- Handheld fundus photograph
- Corneal pachymetry

Ocular Toxicology

Comparative Ophthalmology

To assess test article related ophthalmological toxicity in various animal species of Toxicology studies by examining the anterior and posterior segments of the eye with slit-lamp and indirect ophthalmoscopy.

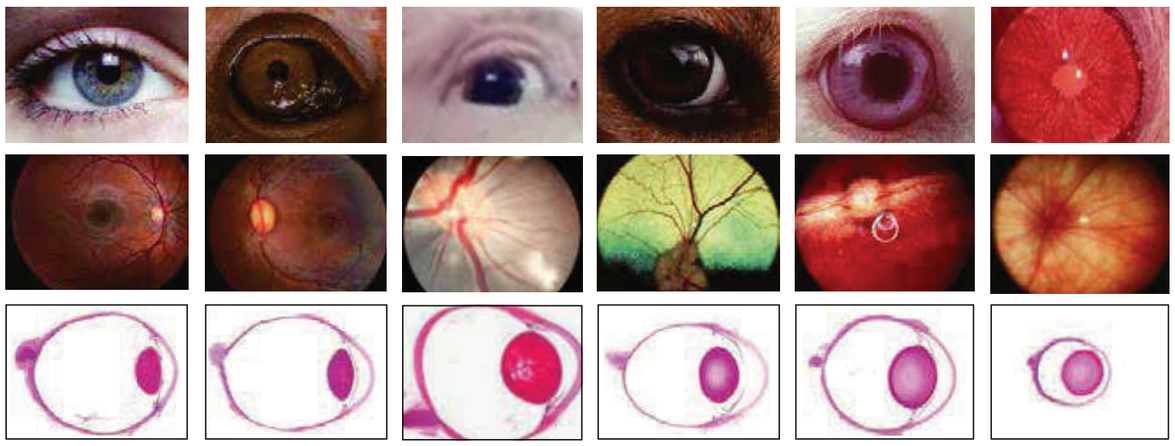

Eye Irritation Evaluation

Eye irritation is the production of changes in the eye following the application of a test substance to the anterior surface of the eye, which are fully reversible within 21 days of application.

Draize scoring method with direct ophthalmoscope

More general examination and evaluation can be done with slit-lamp microscope using Draize scoring method.

McDonald-Shadduck scoring with indirect ophthalmoscope and slit-lamp microscope

More detailed examination and evaluation can be done with slit-lamp microscope using McDonald-Shadduck scoring system.

Ocular Toxicokinetics/ Pharmacokinetics

Our veterinary, pathology, necropsy, and histopathology teams are highly experienced to support ophthalmology studies.

Animal System

- Non-human Primates (NHPs)
- Dogs
- Rabbits
- Rodents
- Bama Miniature Pigs

Study Type

- Single-dose
- Repeated-dose

Dose Route

- Systemic
- Topical
- Intracameral
- Intravitreal
- Subretinal
- Subconjunctival
- Retrobulbar
- Suprachoroidal

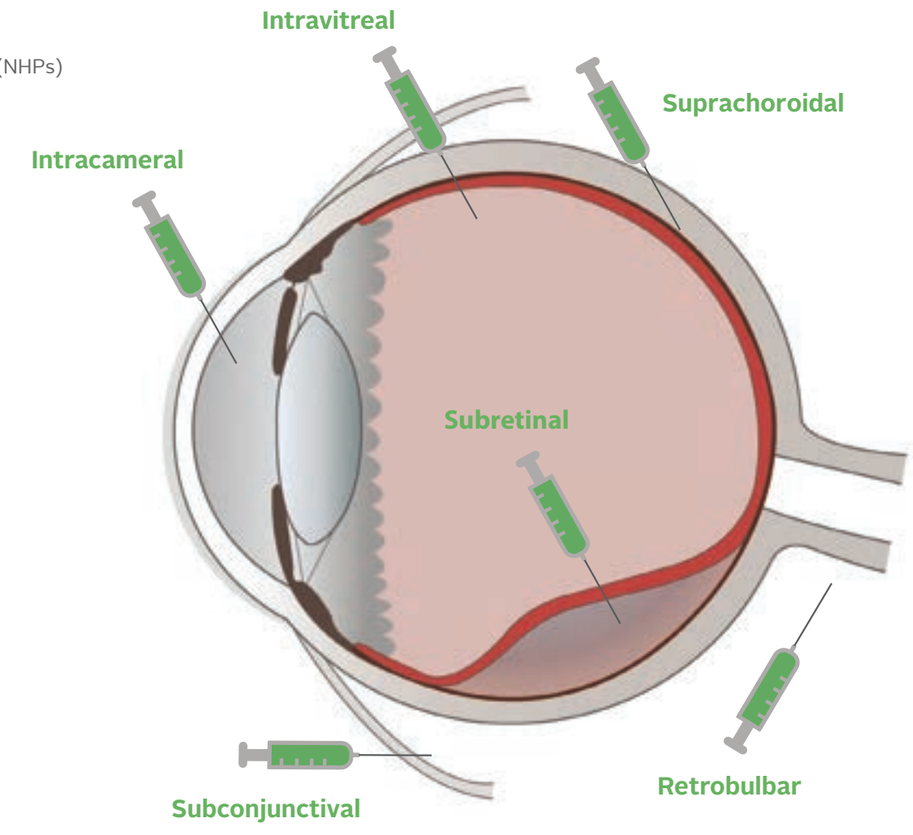

Liquid Sampes Collection

- Aqueous humor
- Vitreous humor
- Plasma, blood and serum
- Tear

Eye Tissue Dissection

- Conjunctivae
- Cornea
- Iris/Ciliary body
- Lens
- Retina/Choroid
- Sclera
- Optic nerve

Evaluation Method

- LC-MS/MS
- Immunohistochemistry
- Enzyme-linked immunosorbent assay (ELISA)
- q-PCR

Case Studies
Pharmacokinetics

Besifloxacin Instillation in Rabbits

A besifloxacin suspension was administered by topical instillation at 0.3 mg/eye in New Zealand White rabbits (n=3). The blood, aqueous humor, vitreous, cornea, lens and tears fluid were collected at predetermined time points (0.083, 1 and 8 h) and analyzed by LC-MS/MS. The highest drug concentration was observed in the tear fluid followed by the conjunctiva, vitreous and aqueous humor. The results are consistent with those reported in the literature.

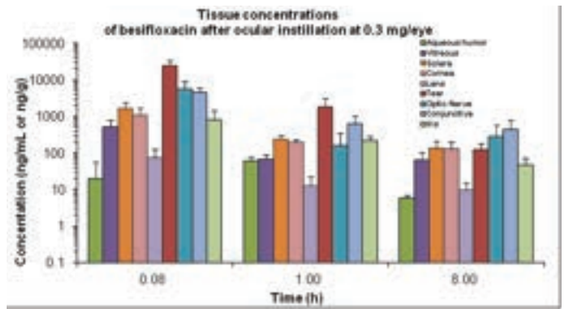

Ocular tissue and blood concentrations of besifloxacin following ocular instillation to New Zealand White rabbits (n=3).

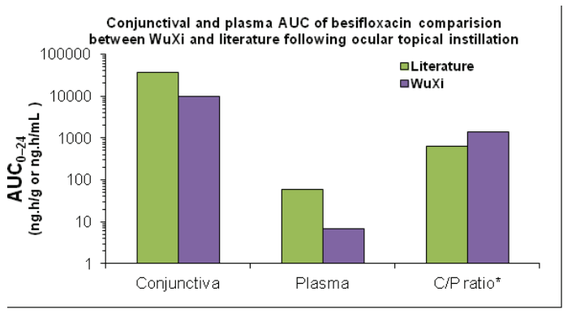

Conjunctival and plasma AUCs following the ocular instillation of besifloxacin conducted by WuXi AppTec DMPK correlate with those in the literature.



Case Studies
Pharmacokinetics

Intravitreal Vancomycin in Rabbits

A solution of vancomycin was administered by intravitreal injection at 1 mg/kg to New Zealand White rabbits (n=3). The blood, aqueous humor, vitreous humor, sclera, cornea and lens were collected at 0.25, 1, 2, 4, 12 and 24 h and analyzed by LC-MS/MS. The concentration vs time curves for each tissue showed the vancomycin was highest in the vitreous while the drug only entered the systemic circulation to a small extent. The obtained PK profiles and parameters were compared to literature values obtained from the same rabbit strain and found to be in agreement as seen in the table.

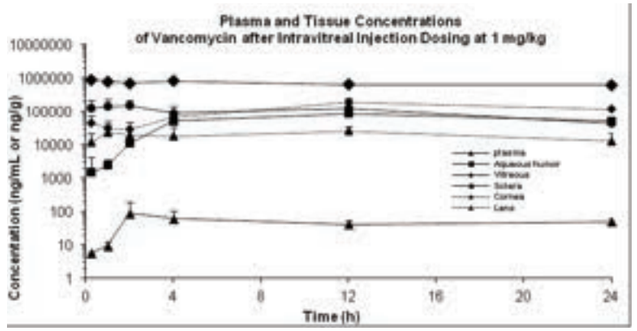

Drug concentration profiles of vancomycin in the plasma and several ocular tissues over 24 h following intravitreal injection to New Zealand White rabbits (n=3).

Tissue	Literature		
	Cmax (µg/g or µg/mL)	Tmax (h)	AUC_{0-24} (µg*h/g or µg*h/mL)
Aqueous Humor	58.03±4.3	12	959.4
Vitreous Humor	997.5±63.4	0.25	7,807.6

Tissue	WuXi AppTec		
	Cmax (µg/g or µg/mL)	Tmax (h)	AUC_{0-24} (µg*h/g or µg*h/mL)
Aqueous Humor	86.5±12.7	12	1,427.7
Vitreous Humor	880 ±170.9	0.25	16,117.4

Comparison of vancomycin PK parameters obtained at WuXi AppTec and those reported in the literature.



Ocular Pharmacology

Animal Models

Cataract
- Selenite injection-induced cataract in rats
- Traumatic cataract in rats

Dry Eye
- Benzalkonium instillation in rabbits or mice
- Scopolamine subcutaneous injection in mice or rabbits
- Atropine tear gland injection in rats
- Lacrimal gland removal in mice
- Dry environment

Eye Surface Disease
- Corneal neovascularization induced by stitching or NaOH burn in rabbits
- Allergic conjunctivitis induced by histamine instillation in rabbits
- Neurotrophic keratopathy in rats
- Corneal wound healing model in rabbits
- Pterygium model in rabbits
- Cornea transplant model in rabbits
- Keratitis and conjunctivitis induced by antigen

Glaucoma
- Acute IOP elevation induced by intracameral injection of viscoat in rabbits or PBS infusion in rats.
- IOP elevation induced by intracameral injection of magnetic microspheres in rats or mice
- IOP elevation induced by episcleral vein or trabecular laser photocoagulation in mice or monkey
- IOP reducing test in various species

Myopia
- LIM in guinea pig
- Near work induced myopia in guinea pig
- FDM in guinea pig

Optic Nerve Injury
- Optic nerve injury induced by clamping in rats
- Partial optic nerve transection in rats

Presbyopia
- Lens elasticity test in mice

Retinopathy
- Choroidal Neovascularization (CNV) induced by laser photocoagulation in mice, rats and NHPs
- Oxygen-induced Retinopathy (OIR) in mice
- Retinopathy induced via light exposure in rats and mice
- Retinopathy induced by sodium iodate in rats, rabbits and NHPs
- Retinal neovascularization induced by DL-AAA in rabbits and NHPs
- Streptozotocin induced diabetic retinopathy in rats
- VEGF induced retinal neovascular in rabbits
- Central Retinal Artery Occlusion (CRAO) in rabbits
- Central Retinal Vein Occlusion (CRVO) in rats, mice and rabbits
- Retinal Tear in rabbits and retinal detachment in mice

Uveitis
- LPS induced uveitis in rats
- Experimental autoimmune uveitis in rats

Case Studies
Pharmacology

Full Sets of Electrophysiology

Demonstrations of electrophysiology examination including the traditional and precise electrophysiology.

Traditional Electrophysiology

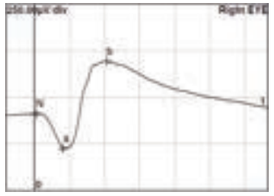
Flash ERG

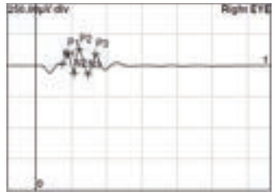
OPs

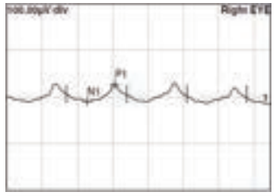
Flicker ERG

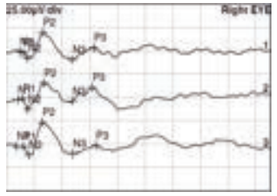
Flash VEP

Precise Electrophysiology

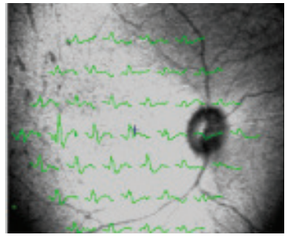
Multi-focal ERG

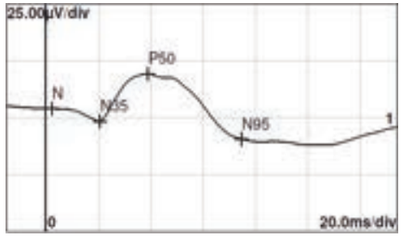

Pattern ERG

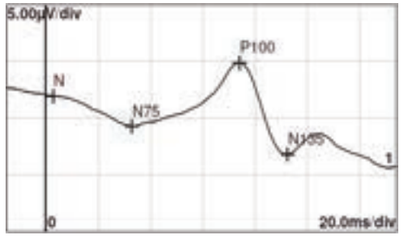

Pattern VEP

VEGF induced retinal vascular leakage in rats

Intravitreal inject VEGF induced retinal vascular leakage in rats. This model could be used for retinal vascular leakage inhibition therapy evaluation, e.g., CNV and DME (diabetic macular edema).

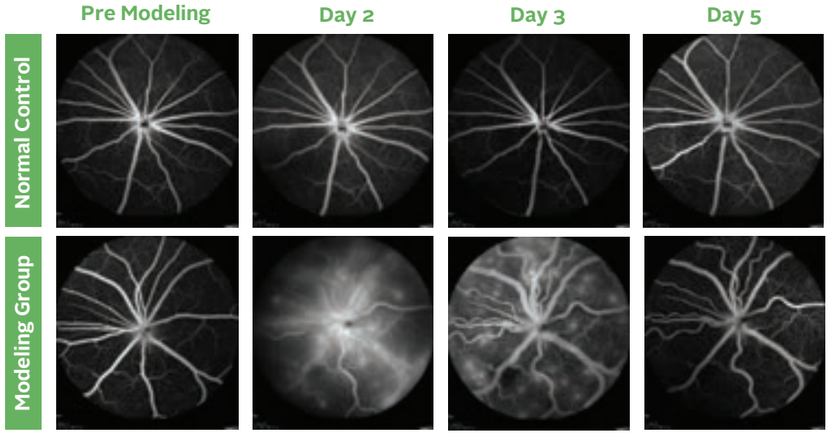

Case Studies
Pharmacology

Choroidal Neovascularization in NHP

Demonstration of CNV in NHP induced by laser photocoagulation. Laser was shot at eight spots surround the macular. OCT indicated that the Bruch's membrane was broken through. Two weeks post modeling, FFA showed hyperfluorescein at the laser spots.

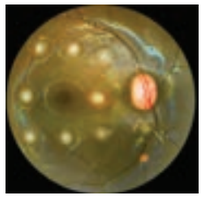

Laser
Photocoagulation

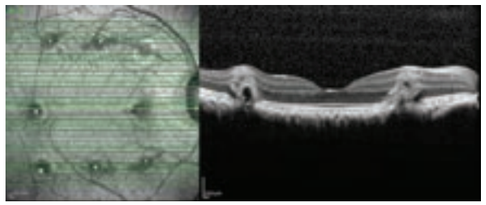

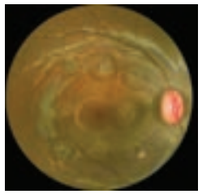

Post-Modeling
Week 2

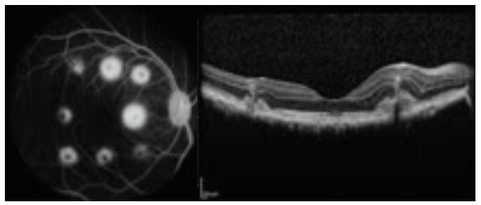

Spontaneous Macular Degeneration

Macular degeneration was found in un-treated young NHP. With multi-focal ERG examination, the retinal function of macular can be demonstrated. Healthy normal retina shows peak signal at the macular, but the peak is absent in animals with macular degeneration. This model has the potential to be used for junior macular degeneration efficacy research.

Normal Macular

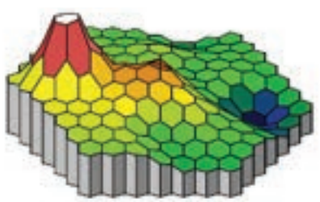

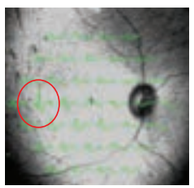

Macular with Drusen

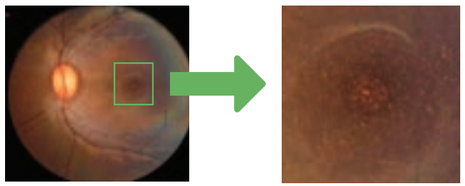

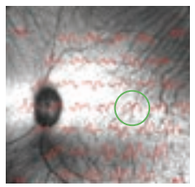

Case Studies
Pharmacology

Spontaneous Macular Degeneration in NHP --- Large Drusens

Parafoveal drusen was found in un-treated young NHP. Fundus photo showed yellow-white dots surrounding the macular especially temporal to the macular. OCT showed the abnormality happened at the RPE and IS/OS layers. FFA and autofluorescein both showed hyperfluorescein.

Fundus Photo

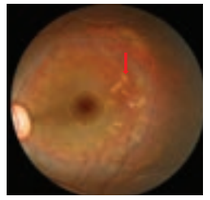

SLO



OCT

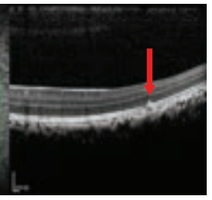

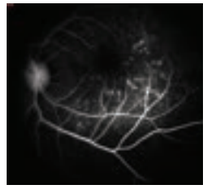

FFA

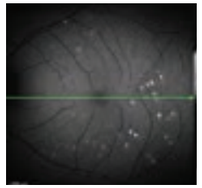

AFA

Corneal Neovascularization (CRNV) in Rabbits

Corneal neovascularization (CRNV) model in rabbits can be induced by corneal suture and corneal alkali burn. CRNV was clearly observed from Day 3~4 post-modeling. With treatment of steroid, the CRNV could be inhibited.

Suture

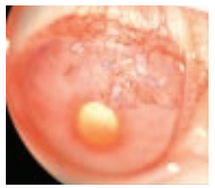

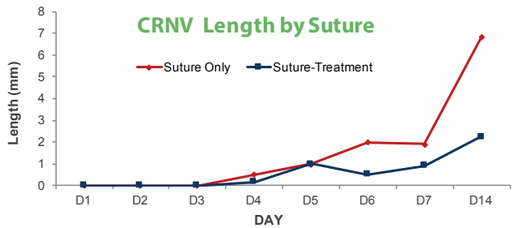

Alkali Burn

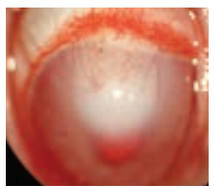

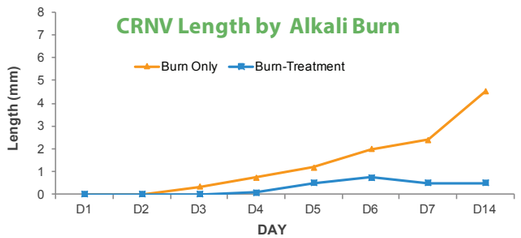

Case Studies
Pharmacology

Dry Eye Induced by BAC Instillation in Rabbits

Compared to the normal control eyes, yellow-greenish fluorescein staining on cornea was observed with the corneal fluorescein staining examination, less and out-of-shape goblet cells were observed with the conjunctival impression cytology examination, and with less tear amount was observed with the Shirmer's test. Histology showed that the modeled eye shows less and out-of-shaped goblet cells consisting with the conjunctival impression cytology test.

Corneal Fluorescin Staining

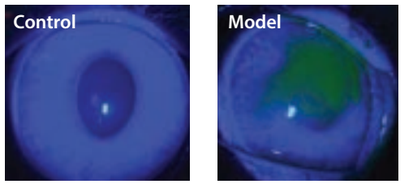

Conjunctival Impression Cytology

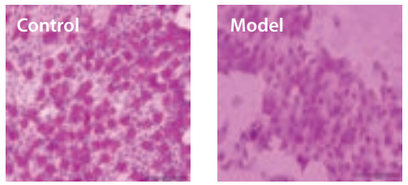

Schirmer's Test

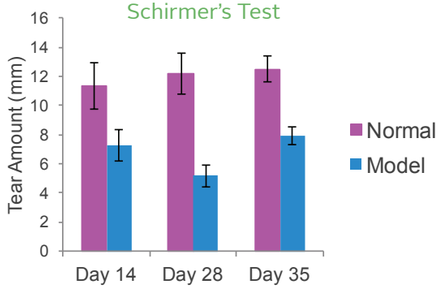

Histology

Acute Glaucoma Model in Rabbits

Acute glaucoma with high IOP lasting for less than 10 hours could be induced by intarcameral injection of viscoelastic substance in rabbits. The ocular hypertension could be maintained during 2~10 hours post-injection. Treatment interference could lower the ocular hypertension.

Induced by intracameral injection of viscoelastic substance

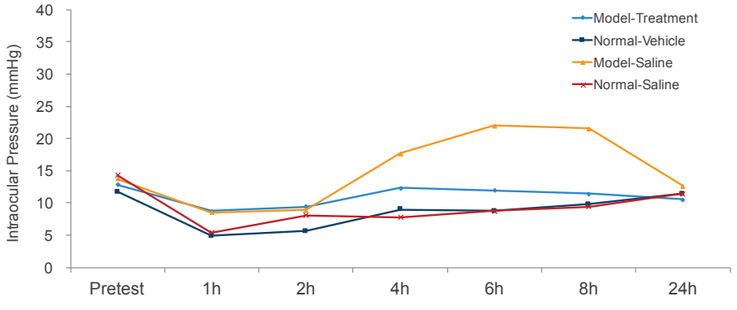

Case Studies
Pharmacology

Chronic Glaucoma Model in Mice

Chronic glaucoma could be induced by laser photocoagulation of the trabecular meshwork in mice. The ocular hypertension could last longer than 3 months.

Induced by laser photocoagulation of the trabecular meshwork

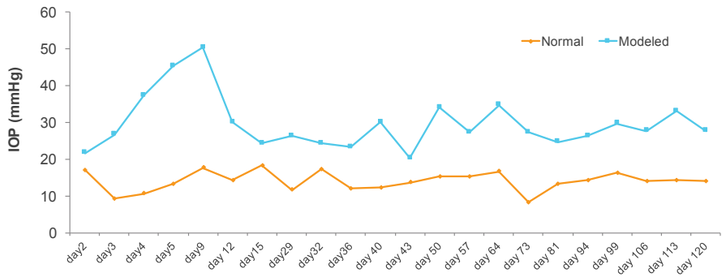

Optic Nerve Injury Model in Rats

Optic nerve injury model in rats could be induced by optic nerve clamping. Flash visual evoked potential (VEP) showed delayed N2 and P2 waves and the corresponding amplitude of N1-P2 was lowered. OCT scan showed that the retinal nerve fiber layer (RNFL) became thinner.

Pre-modeling

Post-modeling

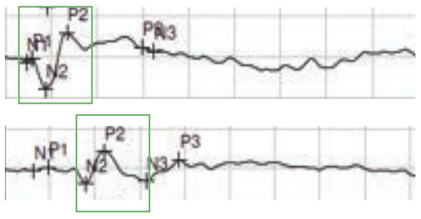

- N2 and P2 were delayed
- Amplitude of N2-P2 was lowered

Thinner retinal neuclear fiber layer (RNFL) post-modeling

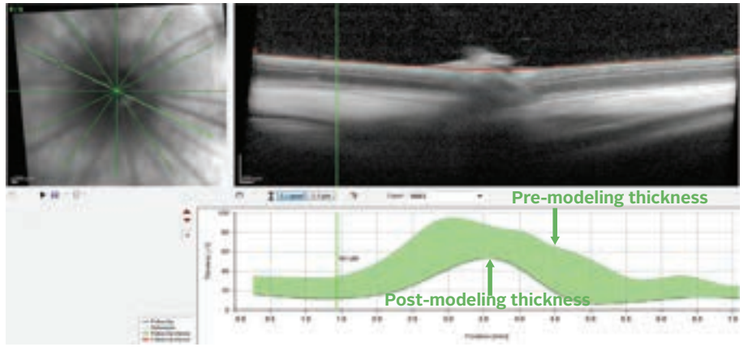

Instrument

The Roland RETImap electrophysiology is designed for animal research which tests retinal and optic nerve functions. It provides not only the traditional electrophysiology testing such as full-field ERG and flash VEP, but also précised measurement including multi-focal ERG, pattern ERG, and pattern VEP.



Roland Full-field/multi-focal Electrophysiology



Heidelberg Bluepeak Optical coherence tomography (OCT) is a non-invasive imaging test using light waves to take cross-section pictures of both posterior and anterior segments of eyes. The examination can be performed in various species from rodents to large animals.

Heidelberg Bluepeak OCT + AF

Kanghua fundus camera enables fundus photo (FP) and fundus fluorescein angiography (FFA). Due to optical system difference, we have two pieces of this equipment, one for rodents and the other one for large animals. The retinal changes especially blood vessel abnormalities can be refelcted.

Kanghua FP + FFA

Welch Allyn binocular ophthalmoscope and Kowa protable slit-lamp and fundus camera are used to do general ocular examination.

Welch Allyn Binocular Ophthalmoscope

Kowa-SL-17 Portable Slit-lamp

Kowa Potable Fundus Camera

Three pieces of iCare tonometers measure animal intraocular pressure (IOP) in various species. Two TonoLabs are for small animal testing and one TonoVet is for large animal testing.

iCare TonoVet + TonoLab

Instrument

Leica M620 F20 surgery microscope enables ocular operations of dosing (such as intravitreal and sub-retinal injection) and ocular surgeries.

Surgery Microscope

Laser Slit-lamp

Quantel Vitra532 Ophthalmic Laser is used to develop animal disease models. By laser breaking the Bruch's membrane, choroidal neovascularization can grow into retinal so as to simulate exudative AMD. By laser occulsion the episcelral veins, high IOP will be induced so as to simulate glaucoma.

Kanghua table-mounted slit-lamp microscope enables detailed anterior segment examination. The abnormalities can be recorded as images. Basic measurements of length and size can be done with the matched software.



Slit-lamp Microscope

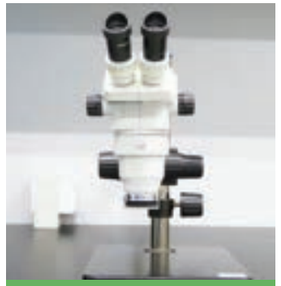

Operating Microscope

WPI stero operating microscope enables ocular operations on small animals.

WPI intraocular kit enables precise intraocular injection in various species.

WPI intraocular kit

WuXi AppTec

Laboratory Testing Division
labtesting.wuxiapptec.com